

Shrimp Bacterial Infections in Latin America: A Review

M.S. MORALES-COVARRUBIAS^{1,*}, J. CUÉLLAR-ANJEL², A. VARELA-MEJÍAS³ and C. ELIZONDO-OVARES⁴

¹Centro de Investigación en Alimentación y Desarrollo A. C. Unidad Mazatlán en Acuicultura y Manejo Ambiental Mazatlán, Sinaloa, México

²Calle 101 #20-33 Bogotá, Colombia

³Laboratorio de Patologías y Parasitología de Crustáceos Golfo de Nicoya, Costa Rica

⁴Servicio Nacional de Sanidad Animal, Programa de Sanidad Acuícola San José, Costa Rica

Abstract

Shrimp aquaculture is an important industry that experiences significant losses from *Vibrio* species and intracellular bacteria, especially at the larval and juvenile stages. This review, which covers the period from 2000 to 2015, summarizes the bacterial diseases in farmed shrimp in Latin America based on information obtained for 12 countries with semi-intensive and intensive farming systems. The presence of five diseases with variable prevalence was determined. The most prevalent disease was septic hepatopancreatic necrosis (SHPN) or “vibriosis”, caused by *Vibrio harveyi*, *V. parahaemolyticus*, *V. alginolyticus* and other species; followed by necrotising hepatopancreatitis (NHP), with an intracellular bacterium as the etiological agent; and then by three emerging diseases, streptococcosis, acute hepatopancreatic necrosis disease (AHPND) and spiroplasmosis.

Keywords: acute hepatopancreatic necrosis disease, bacterial diseases, Latin America, necrotising hepatopancreatitis, *Penaeus vannamei*, septic hepatopancreatic necrosis, spiroplasmosis, streptococcosis, vibriosis

*Corresponding author. E-mail address: marisol@ciad.mx

Introduction

Shrimp farming in Latin American countries contributes about 15 % of world production, with Ecuador, Mexico, Honduras, Nicaragua and Brazil as the countries with the largest productions and having about 180 000, 65 000, 27 397, 23 980 and 20 000 ha of shrimp farming ponds, respectively. Production is destined for export, mainly to markets in the United States of America, Europe and Japan. Although Latin American shrimp production has been increasing, the last decade has been characterized by high prevalence of viral and bacterial diseases in farmed shrimp, probably due to fluctuations in temperature, salinity, oxygen, pH and water nutrients (Lightner 1993). Environmental factors and confinement are two important triggers for the rapid multiplication of opportunistic bacteria, located in the digestive tract, gills and cuticle of shrimp and in the water, feed and pond sediment (Jayabalan et al. 1982; Cuéllar-Anjel et al. 1998). The exoskeleton provides an effective physical barrier against pathogens that try to penetrate the outer surface of crustaceans, while the intestine is another defense barrier to keep out pathogens. However, some chitinoclastic (or chitinolytic) bacteria of the genus *Vibrio* are associated with exoskeleton disease and can also enter through wounds (Álvarez et al. 2000; Barrientos 2010). The gills appear to be susceptible to bacterial penetration because they are covered by thin exoskeleton; however, they are naturally cleaned by the permanent movement of water through the gill chambers and by frequent molting. The midgut and hepatopancreas are not lined by exoskeleton and therefore seem to be likely sites for pathogen penetration via water, feed and sediment. Bacterial diseases reported in shrimp farming are mainly caused by *Vibrio harveyi*, *V. parahaemolyticus*, *V. alginolyticus*, *V. nigripulchritudo*, *V. campbellii*, *Pseudomonas* spp., *Aeromonas* spp., *Micrococcus* spp., *Candidatus Hepatobacter penaei* and *Streptococcus* spp. Thus, the aim of this study is to compile the available information on bacterial diseases affecting shrimp-producing countries in Latin America during the past 15 years (Varela 2013; SIVE 2014; Marroquín 2015). A general review conducted to obtain information from 12 Latin American countries with semi-intensive and intensive shrimp farming systems determined the presence of five diseases with variable prevalence. The following are the main bacterial diseases reported, along with their distribution and prevalence in Latin America and their clinical signs.

Previously Known Bacterial Diseases

Septic Hepatopancreatic Necrosis (SHPN), Vibriosis, Systemic Vibriosis or "Seagull Syndrome"

This shrimp disease was reported in all 12 Latin American countries during 2000 to 2015. The average prevalence was 45.5 % (Table 1), with infections being most prevalent in Mexico and Costa Rica (80 %). SHPN has been reported in hatcheries (Lightner and Redman 1994; Cuéllar-Anjel et al. 2000) and grow-out shrimp farms. The main *Vibrio* spp. isolated from shrimp with SHPN were *V. harveyi*, *V. parahaemolyticus*, *V. alginolyticus* and *V. campbellii*. *Photobacterium damsela* (formerly classified as *V. damsela*), *V. fluvialis* and *Vibrio* sp. were also reported in sick animals (Lightner and Lewis 1975).

Table 1. Prevalence of bacterial diseases infecting farmed shrimp (%) in 12 Latin American countries during the period 2000 to 2015.¹

Country	SHPN or Vibriosis	NHP	Streptococcosis	AHPND	Spiroplasmosis
Mexico	80%	75%		60%	
Guatemala	45%	25%	10%		
Belize	35%	40%			
El Salvador	30%				
Honduras	60%	35%			
Nicaragua	30%	20%			
Costa Rica	80%	67%			
Panama	35%	40%			
Colombia	30%	10%			10% (outbreak in 2002) ²
Venezuela	30%	10%			
Ecuador	55%	70%			
Peru	35%	80%			

¹ AHPND = acute hepatopancreatic necrosis disease, NHP = necrotising hepatopancreatitis, SHPN = septic hepatopancreatic necrosis.

² Source: Nunan and Lightner (2005).

SHPN has been diagnosed by classical bacteriology, quantifying the presence of bacteria in haemolymph (1×10^4 cfu.mL⁻¹) and hepatopancreas (1×10^5 cfu.g⁻¹). The wet-mount method was also used for the detection of progressive tubular deformation (Fig. 1), bacterial colonization, cell sloughing, haemocytic nodules and melanized necrotic tubules (Lightner, 1993).

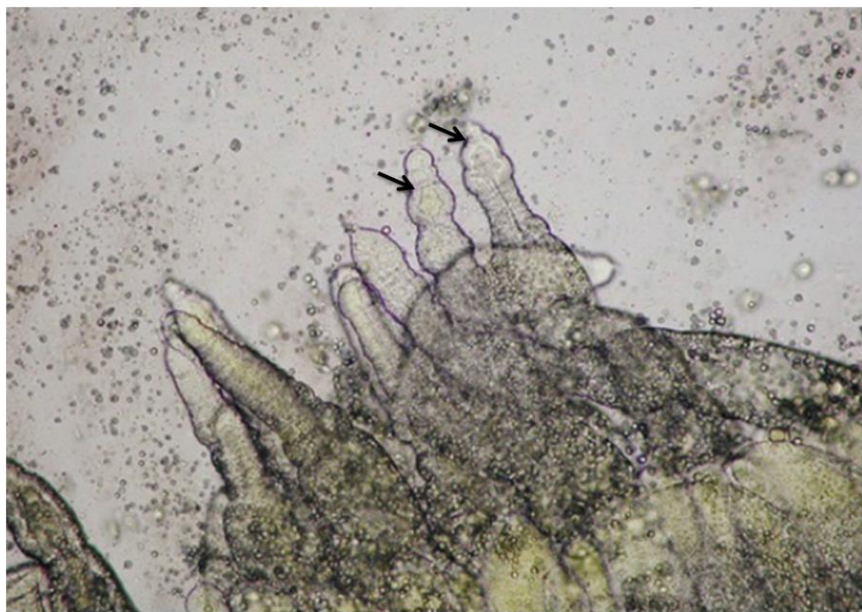


Fig. 1. Wet mount of hepatopancreatic tubules taken from *Penaeus vannamei* showing tubular deformation (arrows) and cellular desquamation.

Histopathological studies complemented the diagnostic process, by which the presence of haemocytic infiltration and nodules with bacterial clusters; hepatopancreatic tubule lumen hypertrophy; cell sloughing; and tubular melanization, necrosis and atrophy (moderate to severe) were confirmed. Haemocyte infiltration and haemocytic nodule formation with bacterial colonies were also reported in the heart (Fig. 2), gills, lymphoid organ, connective tissue, antennal gland, musculature, and caeca, with moderate to high severity.

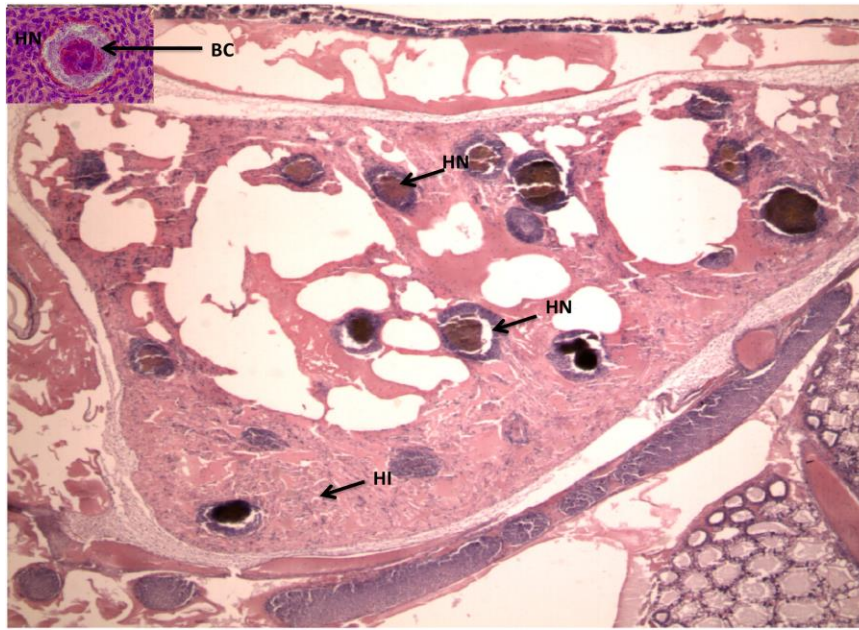


Fig. 2. Histological sections of the heart of *Penaeus vannamei* showing haemocyte infiltration (HI) and haemocytic nodule formation (HN) with bacterial colonies (BC).

Necrotizing Hepatopancreatitis (NHP)

NHP is a disease caused by an intracellular rickettsia-like bacterium recently named as *Hepatobacter penaei*. It has been reported by most Latin American countries, with an average prevalence of 39.27 % (Morales-Covarrubias et al. 2011); Mexico, Peru, and Ecuador reported the highest prevalence (see Table 1). Diagnosis of NHP is done by using a polymerase chain reaction (PCR) test. This was complemented by analysis of wet mounts, through which empty (non-vacuolated) hepatopancreatic tubules, capsule formation (Fig. 3) and melanized tubules with haemocyte infiltration (inflammatory response) were observed (Morales-Covarrubias 2010).

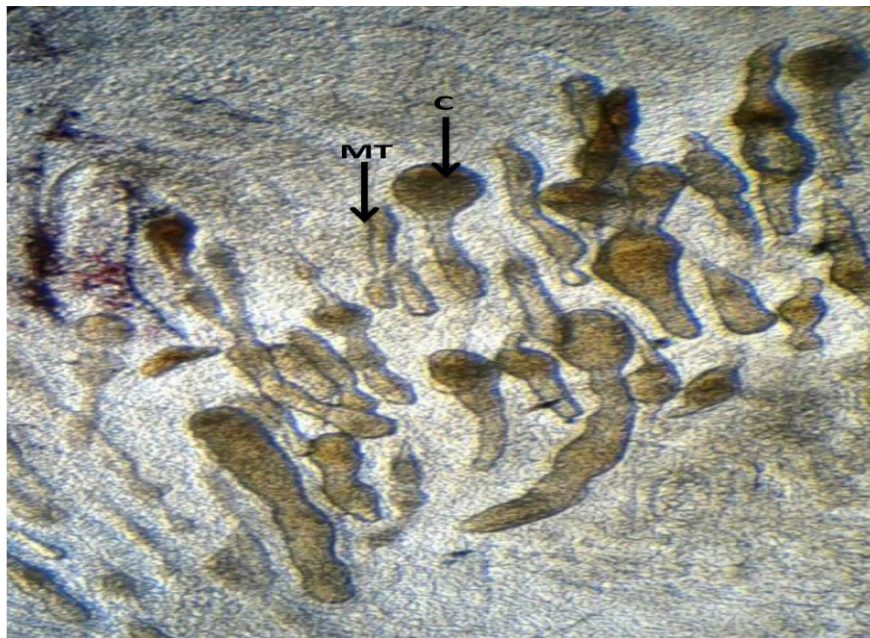

Fig. 3. Wet mount of hepatopancreatic tubules taken from *Penaeus vannamei* showing capsule formation (C) and melanized tubules (MT).

NHP was also diagnosed using histopathology with haematoxylin and eosin (H&E) staining, quantifying damage in the hepatopancreatic tubules such as cell sloughing, tubular atrophy and melanization, the formation of multifocal haemocytic capsules (Fig. 4) involving one or more affected tubules, haemocytic infiltration, presence of epithelial cells within the tubules, and in some cases, clusters of intracytoplasmic bacteria (Morales-Covarrubias et al. 2012).

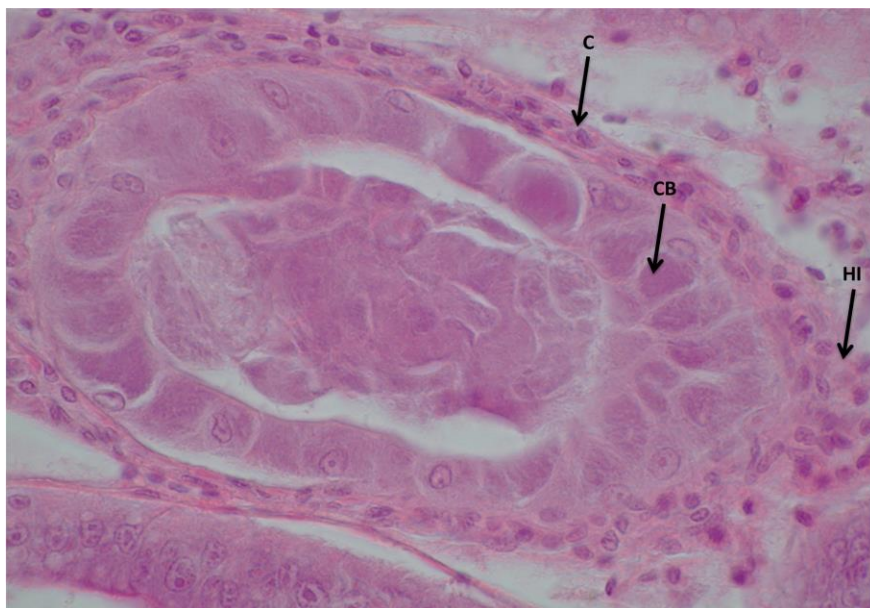


Fig. 4. Histological section of the hepatopancreas of *Penaeus vannamei* showing capsule formation (C) containing intracytoplasmic bacteria (CB) and haemocytic infiltration (HI).

Newly Emerging Diseases

Streptococcosis

This disease has been reported only in Guatemala from 2009 to 2012. It was initially diagnosed using histopathology with H&E staining and by observing haemocytic infiltration, cell sloughing, tubular necrosis and haemocytic nodules (Fig. 5) in the hepatopancreas. Haemocyte infiltration, liquefying necrosis and bacterial mass in the musculature were also observed. Classical bacteriology has been performed to quantify the number of colony forming units (cfu) in haemolymph (10^4 cfu.mL⁻¹) and hepatopancreas (10^6 cfu.g⁻¹) in blood agar. Mortality during the first two years reached 80 %, and *Streptococcus uberis* and *S. parauberis* were identified as causative agents (Hasson et al. 2009; Cazares 2012).

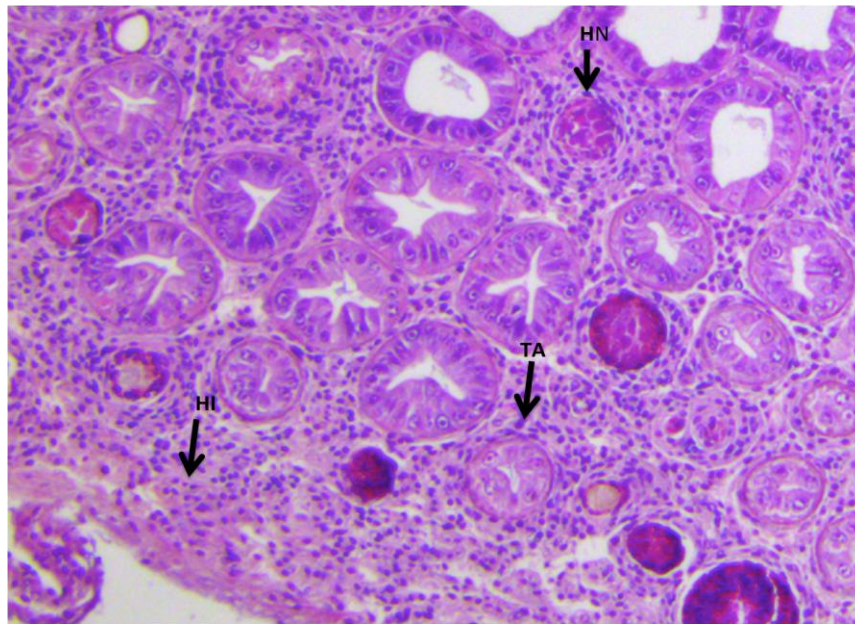


Fig. 5. Histological section of the hepatopancreas of *Penaeus vannamei* showing haemocytic infiltration (HI), multifocal haemocytic nodules (HN), tubular atrophy (TA) and melanized tubules with capsule formation .

Acute Hepatopancreatic Necrosis Disease (AHPND)

AHPND was confirmed in Mexico (first report in the Americas) in August 2013 by Dr Donald V. Lightner from the University of Arizona, during the "Sixth Meeting of the Inter-American Committee on Aquatic Animal Health", held in Yucatán, Mexico. The way by which AHPND came into the country is unknown; it has caused mass mortalities in shrimp production farms culturing *Penaeus vannamei* Boone 1931.

In April 2013, high mortalities were observed in shrimp farms of Nayarit State, Mexico during first 20 days after stocking in semi-intensive and intensive farming systems. Within a few days, mortalities also occurred in other states of the northwest region (i.e. Sinaloa and Sonora), which includes around 90 % of farmed shrimp production in Mexico.

Currently, AHPND is also present in shrimp farms located in the states of Chiapas, Colima and Baja California (Mexicali Valley), the latter two in low salinity (Morales-Covarrubias 2013; Soto-Rodríguez et al. 2015). The first approach to the diagnosis of AHPND, which was made in ponds by observation of clinical signs and wet-mount analysis, established three disease stages: an initial phase, an acute phase and a terminal phase. The initial phase involves normal hepatopancreas colour, tubular deformation (Fig. 6) and hepatopancreatic tubules that are empty at the apical region; these changes become more severe when the shrimp enters the acute phase. In this phase, the hepatopancreas has whitish to pale discolouration and presents central liquefaction when dorsally dissected. In the terminal phase, the hepatopancreas has whitish discolouration, atrophied and melanized tubules, necrosis, clusters of bacteria in the tubules (capsules), and haemocytic encapsulation, and the gut has a whitish content. Methods for confirmatory diagnosis of AHPND include histopathological study of affected shrimp tissues and the use of PCR tests (Tran et al. 2013).

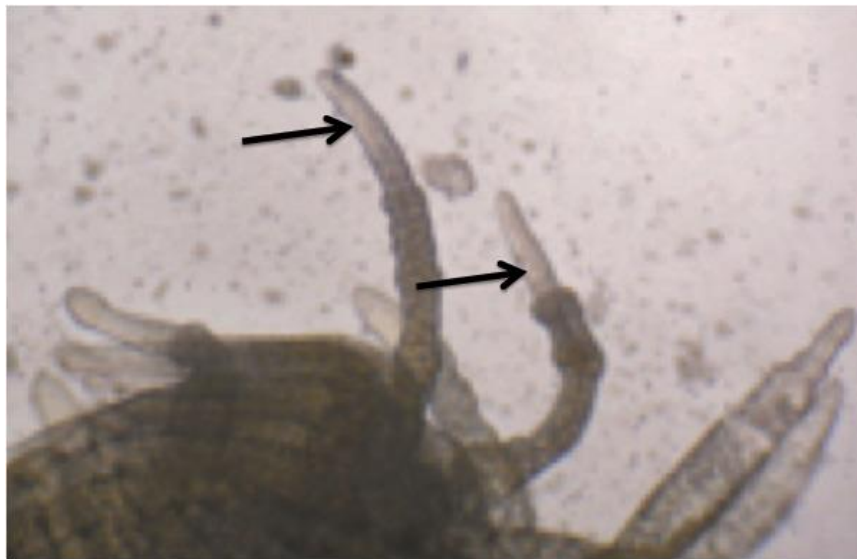


Fig. 6. Wet mount of the hepatopancreatic tubules of *Penaeus vannamei* showing tubular deformation and tubules that are empty at the apical region (arrows).

The same three phases were also observed by histopathology: an initial phase with elongated epithelial cells, non-haemocytic infiltration and bacteria on the gastric mill (Fig. 7). The acute phase had a progressive lesion from the inner (proximal) to the outer (distal) region of the hepatopancreatic tubules, including sloughing of cells into the tubules (Fig. 8); also moderate haemocytic infiltration, cell dysfunction of R, B, F and E cells in the hepatopancreatic tubules, and obvious nuclear hypertrophy in E cells.

The terminal phase presents tubular haemocytic encapsulation, severe haemocytic infiltration and bacterial clusters in the tubule lumen, haemocytic nodules with and without melanization and severe secondary bacterial infection.

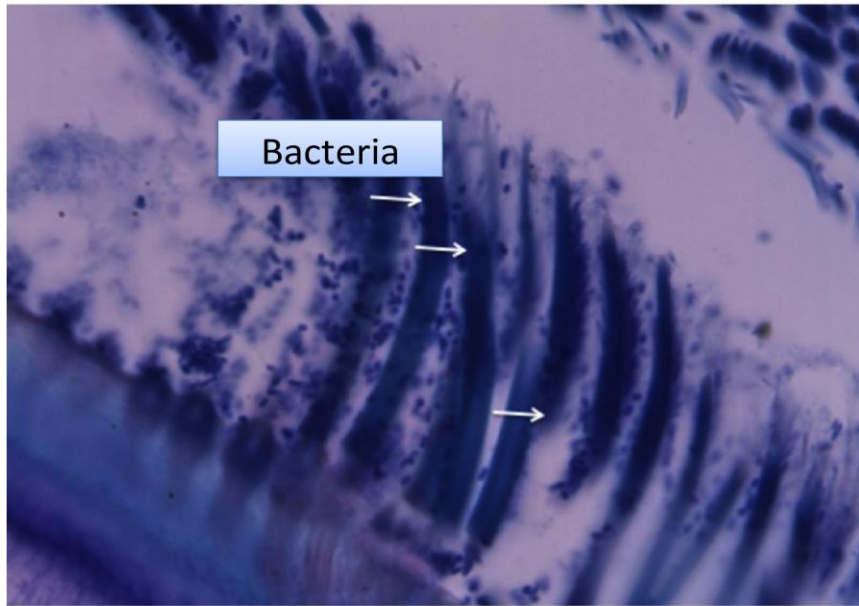


Fig. 7. Histological sections of the gastric mill of *Penaeus vannamei* showing bacterial colonies (arrows).

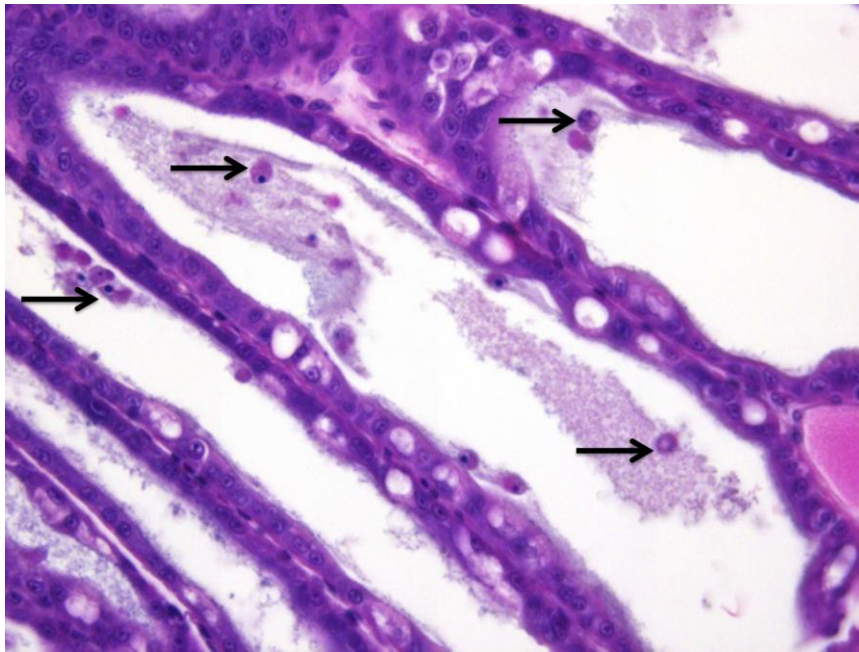


Fig. 8. Histological section of the hepatopancreas of *Penaeus vannamei* showing elongated the hepatopancreatic tubules and sloughing of cells into the tubules (arrows).

Since 2013, Mexico has been the only country in the Americas with reported scientific evidence of AHPND. However, in June 2015, it was suggested that according to PCR analysis in local and foreign laboratories, AHPND is present in populations of farmed *P. vannamei* in Honduras and Nicaragua (Undercurrent News 2015), where mass mortalities were observed in commercial semi-intensive systems. Nevertheless, this has not been confirmed by the competent authorities of these countries.

Spiroplasmosis

This bacterial disease of shrimp is produced by *Spiroplasma penaei*, which was first reported in Colombia in 2002 and has not been detected since in any shrimp farms in the world (Altamiranda et al. 2011). In 2002, spiroplasmosis produced mortalities ranging from 10 to 100 % in commercial shrimp ponds and was initially diagnosed by histopathological study of diseased shrimp, and subsequently by PCR tests (Cuéllar-Anjel et al. 2010). Affected shrimp present no external changes that suggest a bacterial disease; however, expanded chromatophores are sometimes observed. The main histological changes seen in moribund shrimp are lesions typical of systemic bacterial disease and include haemocytic infiltration, multifocal inflammatory foci in several tissues/organs, haemocytic nodules, evidence of phagocytosis, melanization and eventual fibrosis of affected areas (Nunan et al. 2005; Pantoja and Lightner 2014).

Organs and tissues that are affected by *S. penaei* include the ventral nerve cord, skeletal musculature, heart, antennal gland, lymphoid organ, fibrous connective tissue within the hepatopancreas, perigastric spongy connective tissue, gill lamellae and subcuticular epithelium. The disease progression involves the presence of necrotic cells with subsequent migration and aggregation of phagocytic cells into necrotic areas. After necrotic cells and cell-debris phagocytosis, haemocytic nodules appear that degenerate to melanized nodules and finally to a fibrous inflammatory response. For confirmatory diagnosis of *S. penaei*, a combination of histopathology and molecular techniques that include PCR and *in situ* hybridization is suggested (Nunan and Lightner 2005).

Conclusion

Based on the results obtained in this review, it was determined that the highest prevalence of bacterial disease in Latin American farmed shrimp was for septic hepatopancreatic necrosis (SHPN) caused by *V. harveyi*, *V. parahaemolyticus* and *V. alginolyticus*. This disease is probably due to stress during commercial farming and/or environmental changes in recent years. It is likely that the presence of one or more of the reported diseases should be attributed to a deficient or suppressed immune system and a damaged hepatopancreas. It has been reported by Duan et al. (2015) that an affected hepatopancreas promotes the presence, multiplication and spread of pathogens in organs and tissues of farmed shrimp.

This happens because the hepatopancreas performs several functions that include temporary nutrient storage and the synthesis, absorption, secretion and metabolism of lipids and carbohydrates. The hepatopancreas is also involved in the production of proteins required for vital functions, such as the synthesis of haemocyanin, a protein responsible for oxygen transport to all shrimp cells.

The current foci of streptococcosis infections in Guatemala and of AHPND in Mexico are probably due to the fact that these are new (emerging) shrimp diseases in the Americas. It is important to note that at present, most of the bacterial pathogens are adapted to both fresh and marine water, so from the point of pathology and disease control, it is difficult to establish a clear boundary between coastal and marine aquaculture. An inadequate farming environment (e.g. low water and soil quality) can influence shrimp health, increasing susceptibility to pathogens.

The results of this study may help shrimp farmers in implementing preventive measures that are aimed at reducing the risk of spreading bacteria between ponds and farms and to wild ecosystems, thus preventing high mortalities and their associated negative economic impacts for shrimp farms. Because diseases of aquatic organisms may have a variety of sources, it is important to conduct complete and comprehensive diagnostics procedures, covering as many factors as possible, including those related to the production system (e.g. epizootological mapping, climate, farm management, water quality and source of postlarvae). It is also valuable to have integrated health programmes with frequent monitoring plans and surveillance for each country, region and farm to prevent pathogen dispersion. It is urgent that the competent authorities of the countries of Latin America take action on aquatic health and establish strict border controls to protect their own productions and to prevent the entry and spread of transboundary pathogens to and within shrimp farms

References

- Altamiranda, J., M. Salazar and B. Briñez. 2011. Presencia de *Spiroplasma penaei* en plancton, bentos y fauna acompañante en fincas camaroneras de Colombia. *Revista MVZ Córdoba* 16:2576–2583.
- Álvarez, J., A. Álvarez, C. Agurto and B. Austin. 2000. Especies de *Vibrio* y *Aeromonas* aisladas del intestino de camarones marinos sanos silvestres y cultivados en Venezuela. *Veterinaria Tropical* 25:5–27.
- Barrientos, J. 2010. Crecimiento bacteriano en el intestino del langostino *Litopenaeus vannamei*. Tesis para obtener el título en Ingeniería Pesquera. Facultad de Ingeniería Pesquera. Tumbes, Peru, Universidad de Perú. <http://www.scribd.com/doc/40675509/Proyecto-de-Micro>.
- Cazares, E. 2012. Detección de patologías causadas por productos extracelulares de *Streptococcus* sp en camarón blanco *Litopenaeus vannamei* utilizando histopatología. Culiacán, Sinaloa, México, Instituto Tecnológico de Culiacán, Departamento de Ingeniería Bioquímica, pp. 23–26.

- Cuéllar-Anjel, J., J.A. Brock, L.F. Aranguren, R.F. Bador, F. Newmark and L.A. Suárez. 1998. A survey of the main diseases and pathogens of penaeid shrimp farmed in Colombia. Book of Abstracts, World Aquaculture Society Conference “Aquaculture’98”, Las Vegas, USA.
- Cuéllar-Anjel, J., M. Corteel, L. Galli, V. Alday-Sanz and K.W. Hasson. 2010. Principal shrimp infectious diseases, diagnosis and management. In: The shrimp book (ed. V. Alday-Sanz), pp. 517–596. Nottingham University Press, United Kingdom.
- Cuéllar-Anjel, J., V. Pacheco, J. Diez, E. De León, Z. Vega and H. Salazar. 2000. Principales enfermedades de camarones penaeidos cultivados en Panamá. Memorias 4° Congreso Latinoamericano de Acuicultura Panamá, pp. 19–22. (abstract).
- Duan, Y., J. Zhang, H. Dong, Y. Wang, Q. Liu and H. Li. 2015. Oxidative stress response of the black tiger shrimp *Penaeus monodon* to *Vibrio parahaemolyticus* challenge. Fish and Shellfish Immunology 46:354–365.
- Hasson, K.W., E.M. Wyld, Y. Fan, W. Sonia, S.W. Lingsweiller, S.J. Weaver, J. Cheng and P.W. Varner. 2009. Streptococcosis in farmed *Litopenaeus vannamei*: a new emerging bacterial disease of penaeid shrimp. Diseases of Aquatic Organisms 86:93–106.
- Jayabalan, N., R. Chandran, V. Sivakumar and K. Ramamoorthi. 1982. Occurrence of luminescent bacteria in sediment. Current Science 51:710–711.
- Lightner, D.V. 1993. Diseases of cultured penaeid shrimp. In: CRC handbook of mariculture, 2nd edn. Vol. 1, Crustacean aquaculture (ed. J.P. McVey), pp. 393–486. CRC Press Inc., Boca Raton, FL, USA.
- Lightner, D.V. and D.H. Lewis. 1975. A septicemic bacterial disease syndrome of penaeid shrimp. Marine Fisheries Review 37:25–28.
- Lightner D.V. and R.M. Redman. 1994. An epizootic of necrotizing hepatopancreatitis in cultured penaeid shrimp (Crustacea: Decapoda) in northwestern Peru. Aquaculture 122:9–18.
- Marroquín, M. 2015. Situación actual de la camaronicultura en El Salvador. Nota Informativa 25-05-2015 del Ministerio de Agricultura y Ganadería. San Salvador, El Salvador. Ministerio de Agricultura y Ganadería. Informes mensuales de laboratorios, Acuicultura. Programa Acuícola, Servicio Nacional de Salud Animal.
- Morales-Covarrubias, M.S. 2010. Enfermedades del camarón. Detección mediante análisis en fresco e histopatología. Editorial Trillas, SA de CV., Av. Río Churubusco 385, Col. Pedro María Anaya, México, D.F., 2nd edn., 180 pp.
- Morales-Covarrubias, M.S. 2013. Evaluación sanitaria preliminar de granjas camaronícolas con eventos de mortalidades asociados a la necrosis del hepatopáncreas en la región noroeste de México. Informe técnico final. CIAD-INAPESCA.
- Morales-Covarrubias., M.S., A.M. Lemus-Pereira, V.T. Solís-Montiel, A. Ruíz-Luna and G. Conroy. 2011. Prevalencia de enfermedades de camarón blanco (*Litopenaeus vannamei*) cultivado en ocho regiones de latinoamérica. Revista Científica FCV-LUZ 21: 434–446.

- Morales-Covarrubias, M.S., L. Tlahuel-Vargas, I.E. Martínez-Rodríguez, R. Lozano-Olvera and J.M. Palacios-Arriaga. 2012. Necrotisinghepatobacterium (NHPB) infection in *Penaeus vannamei* with florfenicol and oxytetracycline: a comparative experimental study. *Revista Científica FCV-LUZ* 22:72–80.
- Nunan, L.M., D.V. Lightner, M.A. Oduoriand G.E. Gasparich. 2005. *Spiroplasma penaei* sp. nov. associated with mortalities in *Penaeus vannamei*, Pacific white shrimp. *International Journal of Systematic and Evolutionary Microbiology* 55:2317–2322.
- Pantoja, C. and D.V. Lightner. 2014. Espiroplasmosis en camarones. In *Guía Técnica – Patología e inmunología de camarones penaeidos*, (eds. V. Morales & J. Cuéllar-An-jel), pp. 189–191. Panamá City, OIRSA. SIVE. 2014. Sistema Informático de Vigilancia Epidemiológica, Servicio Nacional de Salud Animal. Costa Rica.
- Soto-Rodriguez, S., B. Gomez-Gil, R. Lozano-Olvera, M. Betancourt-Lozano and M.S. Morales-Covarrubias. 2015. Field and experimental evidence of *Vibrio parahaemolyticus* as the causative agent of acute hepatopancreatic necrosis disease of cultured shrimp (*Litopenaeus vannamei*) in northwestern Mexico. *Applied and Environmental Microbiology* 81:1689–1699.
- Tran, L., L. Nunan, R.M. Redman, L.L. Mohny, C.R. Pantoja, K. Fitzsimmons and D.V. Lightner. 2013. Determination of the infectious nature of the agent of acute hepatopancreatic necrosis syndrome affecting penaeid shrimp. *Diseases of Aquatic Organisms* 105:45–55.
- Varela, A. 2013. Enfermedades bacteriales en camarón de cultivo de mayor importancia para C.R. Presentación en el Taller Internacional de Patologías de Camarón Blanco (*Litopenaeus vannamei*) con Fines de Cultivos Comerciales en Costa Rica. Dirección de Investigación, Universidad Técnica Nacional, Sede Puntarenas.
- Whittaker, M. 2015. Honduras, Nicaragua are Central American nations afflicted with EMS. Available at: www.undercurrentnews.com/2015/06/03/sources-honduras-nicaragua-are-central-american-nations-afflicted-with-ems).